

## AN INTEGRATED APPROACH IN THE MANAGEMENT OF VARICOSE ULCER THROUGH AYURVEDA – A CASE REPORT

Dr. Shaik Jeelani Naaz\*<sup>1</sup> BAMS and Dr. P.V. Joshi<sup>2</sup> BAMS MD (Ayu)

<sup>1</sup>2<sup>nd</sup> year P.G Scholar, Department of P.G Studies in Kayachikitsa, Shri Vijaya Mahantesh  
Ayurvedic Medical College and P.G Research Centre, Ilkal, Karnataka, India.

<sup>2</sup>Professor & HOD, Department of P.G Studies in Kayachikitsa, Shri Vijaya Mahantesh  
Ayurvedic Medical College and P.G Research Centre, Ilkal, Karnataka, India.

Article Received on  
02 Feb. 2023,

Revised on 23 Feb. 2023,  
Accepted on 15 March 2023

DOI: 10.20959/wjpr20235-27483

### \*Corresponding Author

Dr. Shaik Jeelani Naaz

2<sup>nd</sup> year P.G Scholar,  
Department of P.G Studies  
in Kayachikitsa, Shri Vijaya  
Mahantesh Ayurvedic  
Medical College and P.G  
Research Centre, Ilkal,  
Karnataka, India.

[jeelaninaaz19@gmail.com](mailto:jeelaninaaz19@gmail.com)

### ABSTRACT

Venous ulcers (varicose ulcers) are the wounds occurring due to inappropriate functioning of venous valves, usually of the legs.<sup>[1]</sup> It is one of the most serious chronic venous insufficiency complications. When a venous valve gets damaged, it prevents the backflow of blood, which causes pressure in the veins that leads to hypertension and, in turn, venous ulcers.<sup>[2]</sup> These are mostly along the medial distal leg, which is often very painful, can bleed, and get infected. In *Ayurveda*, this condition is considered as *Dusthavrana*. It can be managed with the specific *Shodhana* therapy. So, the same treatment protocol was used to treat the case discussed here, i.e. with *Siravyadha*, *Jalaoukavacharana* and by *Basti karma*. The wound was successfully treated and, therefore, is discussed in detail.

**KEYWORDS:** Varicose ulcer, *Dustha vrana*, *Jalaoukavacharana*, *Siravyadha*, *Basti karma*.

### INTRODUCTION

Venous ulcers are caused by venous valves that do not properly prevent the backflow of blood, or venous reflux, where perforating veins transverse the muscular fascia to connect superficial and deep veins. Any condition that causes blood to pool in the veins of the leg is a potential cause of venous ulcers, including varicose veins, deep vein thrombosis or heart failure. A venous ulcer is defined as: full-thickness defect of the skin, most frequently in the ankle region, that fails to heal spontaneously and is sustained by chronic venous disease.

Venous ulcers usually occur at the malleolar region both on the medial and lateral aspects of the ankle. However, they are also known to occur on the supra-malleolar and infra-malleolar regions of the leg and foot, respectively.

Varicose ulcer is a complication of varicose veins or deep vein thrombosis. Varicose veins or DVT which eventually causes chronic Venous hypertension. Causes hemosiderin deposition in the subcutaneous plane from lysed RBC's results in Eczema, Dermatitis, Lipodermatosclerosis<sup>[3]</sup>, Fibrosis, Anoxia and finally results in Ulceration. The annual prevalence of venous leg ulcer among the elderly is 1.69%. The overall incidence rate is 0.76% in men and 1.42% in women.<sup>[4]</sup>

In *Ayurveda Prakupita Vata Dosha* compresses, raises and squeezes the network of veins and is considered as *Krichhra Sadhya Vyadhi* (curable with difficulty) in early stage and *Asadhya* in late stages affecting the vital parts of the body. *Sushruta's* school of thought considers the *Rakta* (blood) as *Dosha*<sup>[5]</sup>, because the blood plays main role in the pathogenesis of many disorders. Because blood vessels are involved, there is definitive involvement of *Pitta Dosha*. Along with *Pitta*, *Vata* alone or *Vata* and *Kapha* are vitiated in their site of affliction, i.e., in weight bearing area like calf and ankle.

Ultimately the imbalanced *Doshas* disturb the vessels and the blood of that particular area (venous blood). Thus the blood is stagnated due to obstruction of the pathway of the blood vessels leading to the cause of *Dushta Vrana*. This can be treated successfully with *Shodhana* (purification) and *Shamana* (pacification) therapy. So, the fore mentioned benefits of *Siravydha*, *jalaoukavacharana* and *Basti* were assessed in alleviating the symptoms and in the healing process of varicose ulcer in the patient.

## CASE REPORT

A male patient of 45 years who was a fruit seller by profession, came with a complaint of ulcer in the medial aspect of right lower limb, since 2 years associated with pricking pain, swelling, burning sensation at swollen area, itching, watery discharge, peeling of skin.

### Chief complaints

- Wound at right foot.
- Swelling and blackish discoloration of skin at right lower limb.

**History of present illness**

Patient was apparently normal before 2 years, gradually developed swelling in the right lower limb at the site of medial aspect of right ankle joint, later having the history of *pidaka* after 6 months which has turned into wound with watery discharge. So, patient consulted to nearby doctor for the treatment of wound, physician advised antibiotics, antacids, ointment and intermittent dressing. Patient continued the treatment for 2 months then got relief. Once again after 3 months wound has reoccurred at same site. Then patient has consulted to our RPK Ayurvedic hospital Ilkal for further treatment.

**History of past illness**

- No H/O DM, HTN or any other medical / surgical illness in the past.

**Personal History**

- Diet : Non-vegetarian
- Appetite : Regular
- Bowel : Once a day, normal
- Micturition : 7-8 times
- Sleep : Disturbed
- Habits : H/o alcohol intake, smoking, since 10 years, no h/o tobacco chewing

**EXAMINATION OF THE PATIENT****General examination**

- GC : Normal
- Pallor : Absent
- Icterus : Absent
- Lymphadenopathy: Mild edema in Right lower limb
- Cyanosis : Absent
- Clubbing : Present
- Oedema : Present

**Vitals**

- Pulse : 80 bpm, Regular
- BP : 120/80 mm of Hg
- Temperature : Afebrile, 97.4°F

- Respiratory rate : 18/min

### **Systemic examination**

- CVS : S1S2 heard
- CNS : Intact, Conscious, oriented to time, place and person
- P/A : Soft, non-tender, No Organomegaly
- RS : Bilateral equal air entry, Normal vesicular breath sounds, no added sounds

### **Wound examination of right leg**

#### **Inspection**

- Location - Anterio-medial aspect of Lower 1/3rd of the right leg
- Discharge – Watery discharge
- Odour – no smell
- Surrounding skin - Blackish discoloration present, mild edema present

#### **Palpation**

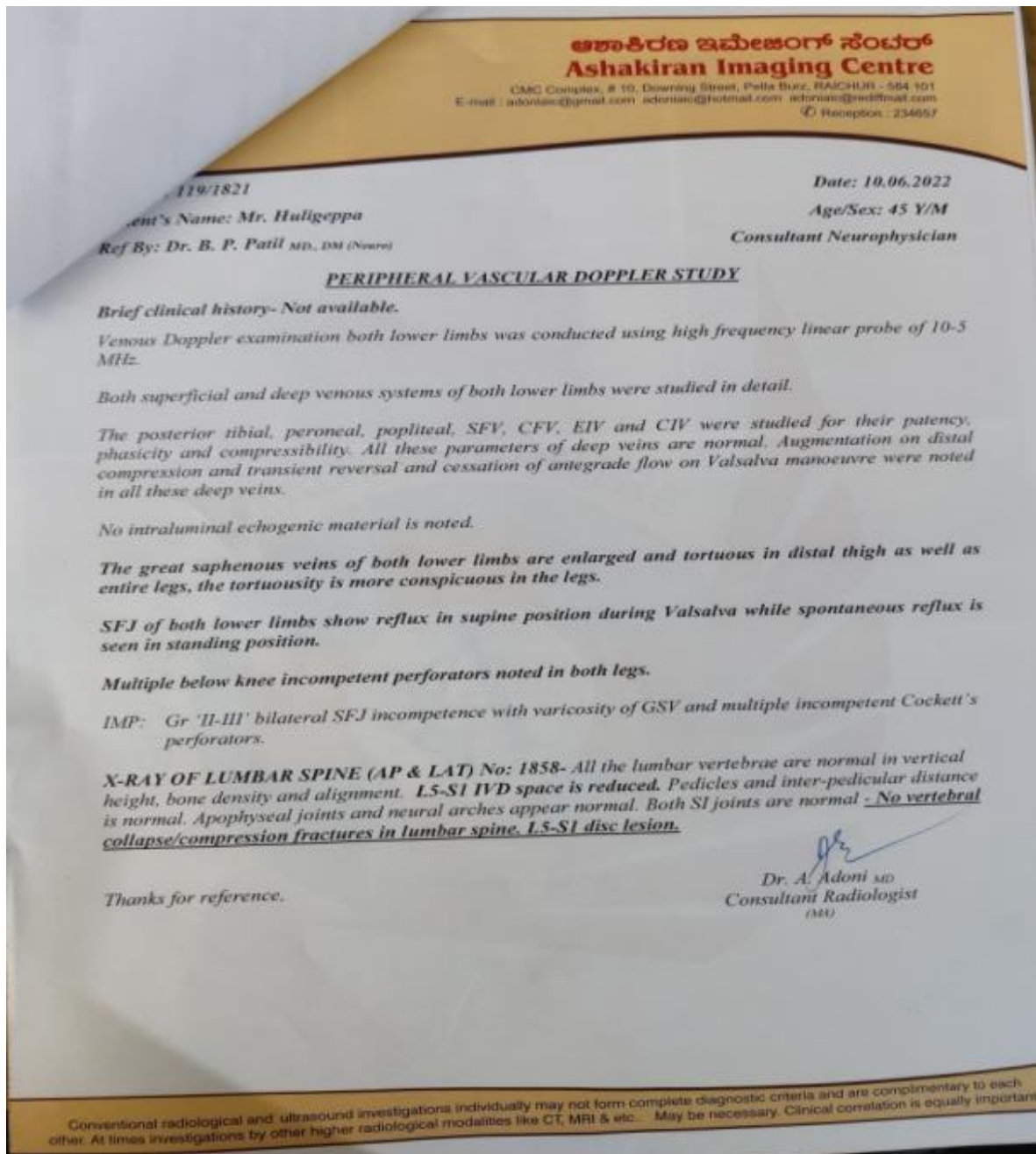
- Temperature - Mildly raised
- Mild tenderness - Present
- Bleed on touch – Absent

#### **Special Examination**

- Morris cough impulse : +ve
- Perth's test : +ve
- Trendelenburg test: +ve
- Mase's sign: +ve

#### **Investigations**

Peripheral vascular Doppler study



Impression: Enlargement of great saphenous vein in both lower limbs and tortuous in distal thigh as well as entire leg but more tortuous in right leg.

### Differential diagnosis

- Diabetic ulcer
- Non-healing ulcer
- Deep vein thrombosis
- Varicose ulcer

**Diagnosis**

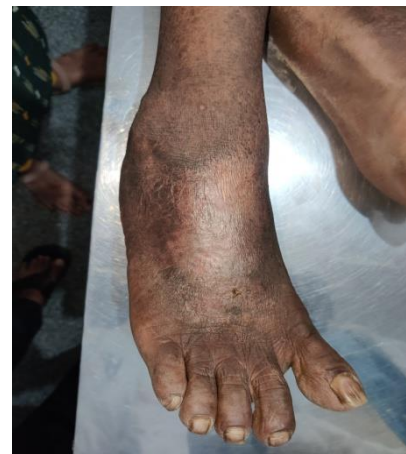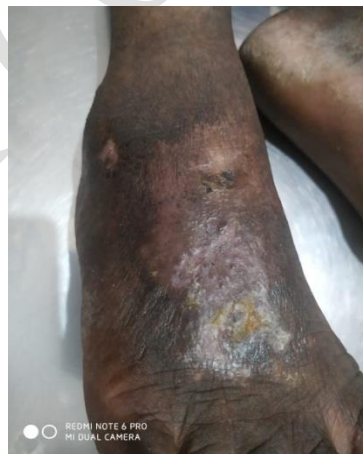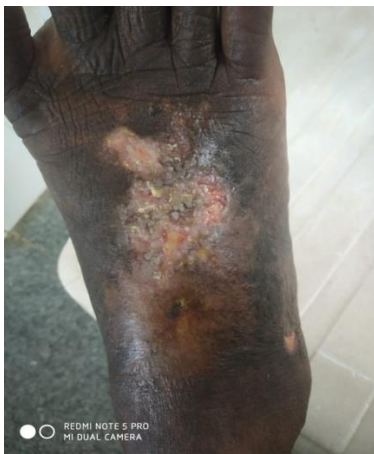Varicose ulcer on the anterior medial aspect of lower 1/3<sup>rd</sup> of Right Leg.

**TREATMENT**

| S.No | Date     | Shamana  | Shodhana   |
|------|----------|--|--|
| 1    | 9/11/22  | <i>Cap. Viscovas</i><br><i>Syp.mahamanjistadi</i><br><i>kashayam</i><br><i>Syp. Punarnavadi kashyam</i><br><i>Pinda taila- E/A</i> |  |
| 2    | 16/11/22 | Same treatment continued   | Advised for <i>basti</i> with<br><i>Bala guduchyadi taila</i><br><i>Shatavari ghrita</i><br><i>Manjistadi niruha basti kwatha churna</i><br><i>m.m oil</i><br><i>pinda taila</i>   |
| 3    | 17/11/22 | <i>Oint. Panchavalkala E/A</i>   | <i>Sarvanga abhyanga</i> with mm oil and <i>baspa swedana</i> .<br><i>Anuvasana basti</i> with <i>manjistadi taila</i> – 100ml<br>Advised for <i>jalaoukacharana</i> .   |
| 4    | 18/11/22 | Same treatment continued   | <i>Sarvanga abhyanga</i> with mm oil and <i>baspa swedana</i> .<br><i>Niruha basti</i> -500ml<br><i>Anuvasana basti</i> with <i>manjistadi taila</i> – 100ml   |
| 5    | 19/11/22 | Same treatment continued   | <i>Sarvanga abhyanga</i> with mm oil and <i>baspa swedana</i> .<br><i>Anuvasana basti</i> with <i>manjistadi taila</i> – 100ml<br>Advised for <i>jalaoukacharana</i> .   |
| 6    | 20/11/22 | Same treatment continued   | <i>Sarvanga abhyanga</i> with mm oil and <i>baspa swedana</i> .<br><i>Niruha basti</i> with <i>manjistadi kashya</i> -500ml  |
| 7    | 21/11/22 | Tab. Fifatrol<br>Same treatment continued  | <i>Sarvanga abhyanga</i> with mm oil and <i>baspa swedana</i> .<br><i>Anuvasana basti</i> with <i>manjistadi taila</i> – 100ml<br>Advised <i>pariseka</i> with <i>triphala kwatha churna</i> &<br><i>panchavalkala kwatha churna</i>           |
| 8    | 22/11/22 | Same treatment continued   | <i>Sarvanga abhyanga</i> with mm oil and <i>baspa swedana</i> .<br><i>Niruha basti</i> with <i>manjisthadi kashya</i> - 500 ml   |
| 9    | 23/11/22 | <i>Cap. Viscovas</i><br><i>Syp.mahamanjistadi</i><br><i>kashayam</i><br><i>Syp. Punarnavadi kashyam</i><br><i>Pinda taila- E/A</i> | <i>Sarvanga abhyanga</i> with mm oil and <i>baspa swedana</i> .<br><i>Anuvasana basti</i> with <i>manjistadi taila</i> – 100ml<br>Advised <i>pariseka</i> with <i>triphala kwatha churna</i> &<br><i>panchavalkala kwatha churna</i>           |
| 10   | 24/11/22 | Same treatment continued   | <i>Sarvanga abhyanga</i> with mm oil and <i>baspa swedana</i> .<br><i>Niruha basti</i> with <i>manjisthadi kashya</i> - 500 ml<br><i>Pariseka</i> with <i>triphala kwatha churna</i> & <i>panchavalkala</i><br><i>kwatha churna</i> & dressing |
| 11   | 25/11/22 | <i>Jatyadi taila E/A</i><br>Same treatment continued   | <i>Sarvanga abhyanga</i> with mm oil and <i>baspa swedana</i> .<br><i>Niruha basti</i> with <i>manjisthadi kashya</i> - 500 ml<br><i>Anuvasana basti</i> with <i>manjistadi taila</i>  |
| 12   | 26/11/22 | Same treatment continued   | <i>Sarvanga abhyanga</i> with mm oil and <i>baspa swedana</i> .<br><i>Niruha basti</i> with <i>manjisthadi kashya</i> - 500 ml<br><i>Anuvasana basti</i> with <i>manjistadi taila</i>  |



|    |          |  |  |
|----|----------|--|--|
|    |          |  | <i>Parisheka</i> done with <i>triphala kwatha</i> & dressing done.   |
| 13 | 27/11/22 | Same treatment continued   | <i>Sarvanga abhyanga</i> with mm oil and <i>baspa swedana</i> .<br><i>Anuvasana basti</i> with <i>manjistadi taila</i> – 100ml<br><i>Parisheka</i> done with <i>triphala kwatha</i> , <i>panchavalala</i> & dressing done.   |
| 14 | 28/11/22 | Cap. Grab<br>Same treatment continued  | <i>Sarvanga abhyanga</i> with mm oil and <i>baspa swedana</i> .<br><i>Niruha basti</i> with <i>manjisthadi kashya</i> - 500 ml<br><i>Pariseka</i> with <i>triphala kwatha churna</i> & <i>panchavalkala kwatha churna</i> & dressing   |
| 15 | 29/11/22 | Same treatment continued   | <i>Sarvanga abhyanga</i> with mm oil and <i>baspa swedana</i> .<br><i>Anuvasana basti</i> with <i>manjistadi taila</i> – 100ml<br><i>Parisheka</i> done with <i>triphala kwatha</i> , <i>panchavalala</i> & dressing done.   |
| 16 | 30/11/22 | Same treatment continued   | <i>Sarvanga abhyanga</i> with mm oil and <i>baspa swedana</i> .<br><i>Niruha basti</i> with <i>manjisthadi kashya</i> - 500 ml<br><i>Pariseka</i> with <i>triphala kwatha churna</i> & <i>panchavalkala kwatha churna</i> & dressing.<br><i>Anuvasana basti</i> with <i>manjisyadi taila</i> . |
| 17 | 1/12/22  | Same treatment continued   | <i>Sarvanga abhyanga</i> with mm oil and <i>baspa swedana</i> .<br><i>Anuvasana basti</i> with <i>manjistadi taila</i> – 100ml<br><i>Parisheka</i> done with <i>triphala kwatha</i> , <i>panchavalkala</i> & dressing done.<br>Advised for <i>jaloukavacarana</i> .                            |
| 18 | 2/12/22  | <i>Cap. viscovas</i><br><i>Syp. punarvadi kashya</i><br><i>Syp. manjistyadi kashya</i><br>Advice to review after 15 days | <i>Sarvanga abhyanga</i> with mm oil and <i>baspa swedana</i> .<br><i>Anuvasana basti</i> with <i>manjistadi taila</i> – 100ml<br><i>Parisheka</i> done with <i>triphala kwatha</i> , <i>panchavalkala</i> & dressing done.  |



## RESULT

- Complete healing of varicose ulcer.
- All previous signs and symptoms are relieved.
- No post treatment complications.
- No any complications associated with varicose ulcer.

## DISCUSSION

### Probable mode of action

#### ***Basti karma (medicated drug enema)***

In the context of *Vraṇa Cikitsā* (a chapter for the treatment of ulcer-like wound), *Basti Chikitsā* (rectal enema therapy) is mentioned as a *śodhana* or a specific purification therapy where medicines are administered through rectal route. The *Vāta Doshaja Vraṇa* and *Adhaṅkāyaja Vraṇa* (ulcers prone to lower limbs) are treated with *Basti karma* or *āsthāpana Basti* (medicines processed with *kashyam* administered through rectal route).<sup>[6]</sup>

By *jaulaukavacharan* explosion of impure blood takes place, due to local vitiated doshas (toxins & unwanted metabolites) are removed. Similarly, it facilitates fresh blood supply & promotes wound healing by formation of “healthy newer tissues”. Due to improved blood circulation, skin discoloration is corrected and venous valvular dysfunction is also pacified. Thus, it breaks the pathogenesis of “varicosity” at cellular level and helps in wound healing.<sup>[7]</sup>

**Viscovas**, reduces endothelial damage to arteries, reduces platelet aggregation and improves blood circulation. It protects heart from ischemia by modulating mitochondrial structure and energy metabolism of heart tissues.<sup>[8]</sup>

***Mahamanjsthadi kashyam***, detoxifies and dissolves the obstructions in blood flow. *Acharya Sushruta* has mentioned *Manjistha* as *pittasamsamana*. It acts as blood purifier, anti bacterial & antimicrobial action because it contains natural substances like tannins and sulfur natural substances that have ability to eliminate bacterial infections. It also having the anti inflammatory effect, contains salicylates and triterpenoids substances that alleviate swelling or inflammation, also helpful in skin disorders and heals the wound.<sup>[9]</sup>

***Punarnavadi kashyam***, highly beneficial in edema and also in inflammatory conditions. As it contains nimba it is having the wound healing and antimicrobial action.<sup>[10]</sup>

***Pinda taila***, possessing topical analgesics and anti inflammatory properties. It pacifies pitta and vata doshas. It is useful in gouty arthritis, relief from pain, lessens burning sensation, decrease redness and inflammation.<sup>[11]</sup>

***Jatyadi tailam***, used externally in restoring and reinforcing the body’s healing mechanism. It dissolves hard fibrous tissue and generates healthy base for healing.<sup>[12]</sup>



*Panchavalkala*, having properties *shodhana* and *ropana*, having *kashya rasa* which is useful in management in *vrana* and *shotha*. It is powerful antiseptic which is also has anti-inflammatory properties. It is also an efficient anti microbial, anti bacterial, and anti fungal.<sup>[13]</sup>

## CONCLUSION

Therapeutic procedures, *Śodhana* (purification therapy), like *siravyadha*, *jalaoukavacharana* and *Basti karma* act on non-healing ulcers and help them heal. Varicose ulcer is one of the serious complications of Varicose veins which can lead to various manifestations like Septicemia, Cellulitis, Venous Eczema, Osteomyelitis, Periostitis ankylosis of ankle joint, rarely Malignancy and will affect day to day routine work. The prevalence of Varicose ulcer is on the increase with chronic venous insufficiency being the main culprit. A detailed accurate assessment of leg ulcer in patients is essential to ensure starting of timely and appropriate treatment. It should be an ongoing continuous assessment as signs and symptoms can rapidly change thereby requiring progressive evaluation. Good and accurate quality patient assessment will save time and cost by an enforcement of appropriate treatment regimens. This approach accelerates the wound healing causing less hospitalization, less economic burden ultimately leading to a healthy life.

## REFERENCES

1. Venous ulcer. [Last accessed on 2013 Mar 21]. Available from: [http://www.en.wikipedia.org/wiki/Venous\\_ulcer](http://www.en.wikipedia.org/wiki/Venous_ulcer).
2. Das S. 1st ed. Diseases of veins edition published by S. Das publication 13, old mayors' court Calcutta; A concise textbook of surgery.
3. Dr. Soman Das, A Concise Textbook of Surgery, by, 5th edition, 2008, published by Dr.S.Das, 13, Old Mayor's Court, Calcutta, 1, 3,211 and 212.
4. Margolis, Bilker W, Santanna J, Baumgarten M. Venous leg ulcer: Incidence and prevalence in the elderly. J Am Acad Dermatol, 2002; 46: 381–6. [PubMed] [Google Scholar]
5. Sushruta. SUSHRUTA SAMHITA (shri dalhana acharya & shri gayadasa virachita hindi vyaakhya), Dr Kevala krushna takaraal (Eds and translator). First part. Chaukhambha Orientalia Varanasi. Reprint Edition 2019. Sutra sthana 21/3.
6. <http://www.ancientscienceoflife.org>

7. International Journal Of Scientific & Technology Research, May 2016; 5(05). Issn 2277-8616, by Deepa Patil, Sangeeta H. Jahagirdhar.
8. <https://www.ayurvedinfo.com>
9. <https://www.planetaryurveda.com>
10. <https://www.planetaryurveda.com>
11. <https://www.planetaryurveda.com>
12. <https://jaims.in>, E-ISSN:2456-3110, by kumar PH P, gopikrishna B, N Rao.
13. <https://jaims.in>, E-ISSN:2456-3110, by kumar PH P, gopikrishna B, N Rao.